

# Cervical spine motion: a fluoroscopic comparison of Shikani Optical Stylet® vs Macintosh laryngoscope

*[Mouvement de la colonne cervicale : une comparaison fluoroscopique entre le Stylet optique Shikani® et le laryngoscope Macintosh]*

Timothy P. Turkstra MD M Eng FRCPC,\* David M. Pelz MD FRCPC,† A. Allison Shaikh MD,†  
Rosemary A. Craen MB BS FRCPC\*

**Purpose:** The optimal technique to manage the airway in patients presenting with a potential or documented cervical spine (C-spine) injury remains unresolved. Using fluoroscopic video assessment, C-spine motion during laryngoscopy with a Shikani Optical Stylet® (SOS) was compared to C-spine motion during intubation using a Macintosh blade.

**Methods:** Twenty-four healthy surgical patients gave written consent to participate in a crossover randomized controlled trial; all patients were subjected to both Macintosh and Shikani laryngoscopy with manual inline stabilization following induction of anesthesia. The C-spine motion was examined at four areas: the occiput-C1 junction, C1-C2 junction, C2-C5 motion segment, and C5-thoracic motion segment. The time required for laryngoscopy was also measured (duration > 120 sec was deemed a failure of the laryngoscopy technique).

**Results:** On average, C-spine motion was 52% less ( $P < 0.02$ ) at three of the motion segments studied, occiput-C1, C2-C5, and C5-thoracic when comparing SOS vs Macintosh laryngoscopy. There was no difference between techniques at the C1-C2 segment. Laryngoscopy with SOS ( $28 \pm 17$  sec) took longer than with Macintosh blade ( $17 \pm 7$  sec),  $P < 0.01$ . There were two failures out of 23 using the SOS, vs none with the Macintosh blade.

**Conclusion:** For patients in whom C-spine movement is undesirable, use of the SOS may limit neck movement, while modestly increasing the time required to intubate, and/or the risk of procedure failure.

**Objectif :** La question de la technique optimale de prise en charge des voies aériennes des patients présentant une lésion potentielle ou documentée de la colonne cervicale demeure sans réponse. Par le biais d'une évaluation vidéo fluoroscopique, le mouvement de la colonne cervicale durant la laryngoscopie à l'aide d'un stylet optique Shikani® (SOS) a été comparé au même mouvement durant l'intubation effectuée avec une lame Macintosh.

**Méthode :** Vingt-quatre patients chirurgicaux sains ont accepté par écrit de participer à une étude randomisée contrôlée croisée ; tous les patients ont eu une laryngoscopie avec lame Macintosh et stylet optique Shikani®, avec stabilisation manuelle en ligne, suite à l'induction de l'anesthésie. Le mouvement de la colonne cervicale a été observé à quatre endroits : la jonction occipitale-C1, la jonction C1-C2, le segment de mouvement C2-C5, et le segment de mouvement C5-thoracique. Le temps requis pour la laryngoscopie a également été mesuré (si la durée > 120 sec, nous avons considéré cela comme un échec de la technique laryngoscopique).

**Résultats :** Le mouvement de la colonne cervicale était en moyenne 52 % moins important ( $P < 0,02$ ) à trois des segments de mouvements étudiés – occiput-C1, C2-C5, et C5-thoracique, en comparant la laryngoscopie avec SOS vs avec Macintosh. Aucune différence entre les techniques n'a été observée au segment C1-C2. La laryngoscopie avec SOS a nécessité  $28 \pm 17$  sec en comparaison d'un temps de laryngoscopie plus court avec la lame Macintosh ( $17 \pm 7$  sec,  $P < 0,01$  vs SOS). Deux échecs sur 23 ont eu lieu lors de l'utilisation du SOS, vs aucun avec la lame Macintosh.

**Conclusion :** Chez les patients où le mouvement de la colonne cervicale est à éviter, le recours au SOS peut limiter le mouvement du cou tout en augmentant quelque peu le temps nécessaire à l'intubation et/ou le risque d'un échec de la procédure.

CAN J ANESTH 2007 / 54: 6 / pp 441-447

From the Department of Anesthesia and Perioperative Medicine,\* and the Department of Diagnostic Radiology and Nuclear Medicine, Neuro-radiology Section,† University of Western Ontario, London, Ontario, Canada.

Address correspondence to: Dr. T. Turkstra, Department of Anesthesia and Perioperative Medicine, University of Western Ontario, Room C3-104, London Health Sciences Centre, 339 Windermere Rd, London, Ontario N6A 5A5, Canada. Phone: 519-685-8500, ext. 35677; Fax: 519-663-2957; E-mail: timothy.turkstra@londonhospitals.ca

Accepted for publication December 21, 2006.

Revision accepted March 7, 2007.

**T**HERE is potential for spinal cord damage during tracheal intubation whenever the cervical spine (C-spine) is unstable.<sup>1-3</sup> Our previous study demonstrated that maximal C-spine movement occurs during intubation, as opposed to the movement observed with careful bag-mask ventilation, making the choice of intubating technique germane.<sup>4</sup>

The Shikani Optical Stylet® (SOS; Clarus Medical, Minneapolis, MN, USA) has unique features which may be advantageous for managing patients with unstable C-spine injuries. This recently-introduced rigid, but malleable, fiberoptic endoscope has a shape similar to that of a lighted intubating stylet or Lightwand. To use the SOS, the endotracheal tube (ETT) is preloaded over the SOS, and both are guided to the glottic opening in a maneuver similar to that used for the Lightwand. The SOS provides a light signature similar to the Lightwand, but with the additional advantage of a fiberoptic view of the vocal cords.

Previous studies have evaluated direct Macintosh laryngoscopy, Bullard laryngoscopy, ventilation via bag and mask, fiberoptic-guided oral and nasal intubation, esophageal Combitube®, cricothyrotomy, Laryngeal Mask Airway®, and the Intubating Laryngeal Mask Airway with respect to C-spine movement during tracheal intubation.<sup>5-12</sup> Recently, studies of the lighted intubating stylet (Trachlight®) and Bonfils® Stylet have been published.<sup>4,13</sup> Only the Trachlight has been shown to reduce C-spine movement without a significant increase in laryngoscopy duration; however the Trachlight involves a blind technique. The instrument shape and insertion technique are similar for the SOS and the Trachlight; the reduced C-spine movement with the Trachlight that was previously shown<sup>4</sup> suggests similarly reduced C-spine movement with the SOS, with a potential advantage offered by the added fiberoptic view. No study to date has specifically examined C-spine movement associated with the use of the SOS.

This prospective randomized controlled crossover trial evaluated C-spine movement during tracheal intubation, comparing the SOS *vs* direct laryngoscopy with a Macintosh 3 blade. The movement of the C-spine was recorded using fluoroscopic video assessment to measure the maximal relative angular displacement of the vertebrae, to test the null hypothesis that intubation using the SOS would result in no difference in C-spine movement compared to direct Macintosh laryngoscopy. The secondary endpoint was time to accomplish laryngoscopy.

## Methods

Approval for the study was obtained from the University of Western Ontario Health Sciences Research Ethics Board for Research Involving Human Subjects. The trial was registered at ClinicalTrials.gov (NCT00310999). Informed and written consent was obtained from each subject.

Inclusion criteria included: ASA physical status I-III patients, age 18-75 yr, undergoing elective non-cardiac surgery requiring general anesthesia with endotracheal intubation. Exclusion criteria included: gastroesophageal reflux disease, body mass index > 35 kg·m<sup>-2</sup>, possibility of pregnancy, previous neck surgery, unstable C-spine, or known difficult airway. Preoperative clinical assessment of the patients included height, weight, ASA physical status, Mallampati score, dentition, thyromental distance, and neck mobility.

While awake, patients were placed on the operating room (OR) table with a rigid board beneath them to simulate field spinal precautions or the table on which trauma patients are placed in the emergency room. The patient's head rested on a pillow in a position judged by the patient to be neutral. After verification that the subject was properly centered, the fluoroscopy unit and OR table remained fixed for the remainder of the study for that subject. Standard monitors were placed. After breathing 100% oxygen for three minutes, anesthesia was induced with fentanyl 2-4 µg·kg<sup>-1</sup> *iv* and propofol 2-3 mg·kg<sup>-1</sup> *iv*. Upon loss of lid reflex, paralysis was induced with rocuronium 0.8 mg·kg<sup>-1</sup> *iv*.

Manual in-line stabilization was provided by an assistant with Advanced Trauma Life Support certification. Care was taken to avoid obscuring the radiographic landmarks during the fluoroscopy. Study personnel used radiation resistant surgical gloves and eyewear as well as upper and lower lead aprons with thyroid protection; patients were shielded with lead aprons for areas not under investigation.

After positioning, a sealed envelope containing a computer-generated random assignment was opened, assigning patients to: Group 1 - Macintosh laryngoscopy first, followed by SOS laryngoscopy, or Group 2 - SOS laryngoscopy first, followed by Macintosh laryngoscopy. All patients underwent laryngoscopy using both techniques. The order of laryngoscopy was randomized to prevent a consistent bias in favour of one group. Block randomization was used to ensure an equal number of patients in each group.

After stabilization was completed, the operator ventilated the patient's lungs with sevoflurane in 100% oxygen via bag and mask until 90 sec had elapsed from

the administration of rocuronium. To minimize neck extension, a low threshold was adopted for use of an oral airway. Patients immediately thereafter underwent laryngoscopy using the two assigned techniques. Intubation was completed as part of the second laryngoscopy. C-spine movement was recorded with continuous fluoroscopy during both laryngoscopies and intubation. The fluoroscopy was recorded continuously in order that the maximal extent of C-spine movement would be observed. Between laryngoscopies, the patient's lungs were again ventilated with oxygen via bag and mask for one minute to prevent desaturation.

The SOS was used according to the instructions provided by the manufacturer. The original curvature of the SOS, as supplied by the manufacturer, was the initial curve used in each SOS case. No laryngoscope was used in conjunction with the SOS; elevation of the mandible with jaw thrust or tongue retraction was performed, but minimized to limit displacement of the C-spine via connecting structures. With both techniques, the operator attempted to minimize neck movement, accepting the first view<sup>14</sup> that offered a reasonable opportunity to adequately position the ETT at the glottic opening. Intubation completed the study; the rigid board was removed and anesthesia and surgery continued in the usual fashion.

All laryngoscopies were performed by one person (T.T.) to minimize inter-operator variability. Prior to this study, T.T. had performed > 60 intubations with the SOS. The fluoroscopy video monitor was not visible to the laryngoscopist during the study.

#### *Study data and data analyses*

Similar to previous work,<sup>4</sup> fluoroscopy of the C-spine during laryngoscopy and intubation was recorded at 4 frames·sec<sup>-1</sup> by a digital video fluoroscopy unit (series 9800 mobile C-Arm with vascular package and 1k × 1k video monitor, GE Medical Systems, Salt Lake City, UT, USA) for review by two radiologists to assess cervical vertebrae movement. The fluoroscopic video was analyzed using Centricity software (GE Centricity Picture Archiving and Communication System, Version 2.1.1.2, GE Medical Systems) to determine the duration of laryngoscopy. Duration was defined as the time from when the blade or stylet passed the central incisors to the time when the ETT was positioned at the vocal cords. If the laryngoscopy sequence took longer than 120 sec, it was deemed a failure.

Using the radiology software, the orientation in the sagittal plane of the occiput and C1 through C5-C7 can be determined at any frame (point in time)

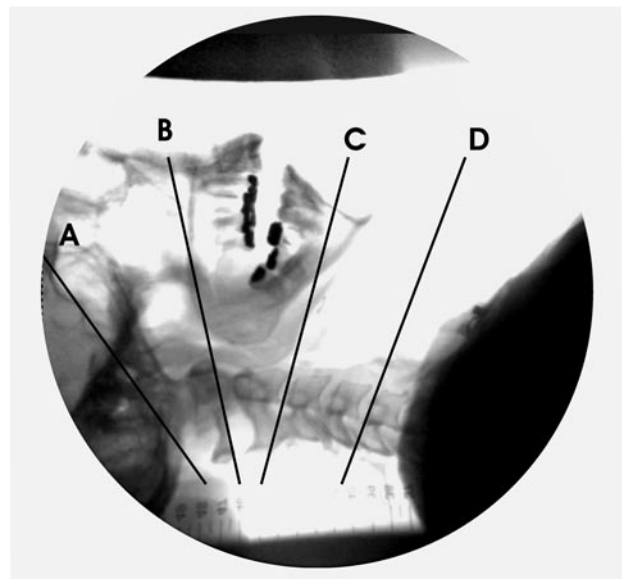


FIGURE 1 Vertebral reference lines

The reference for the occiput was defined by a line between the base of the sella and the opisthion (line A). The C1 reference was a line between the lower cortical margin of the anterior arch of C1 and the lower cortical margin of the C1 spinous process (line B). The C2 reference was a line between the anterior, inferior margin of the C2 body and the lower cortical margin of the C2 spinous process (line C). The C5 reference line was a tangent along the superior end-plate of the C5 vertebral body (line D).

The occiput-C1 segment is defined by the angle between lines A and B. The C1-C2 segment is defined by the angle between lines B and C. The C2-C5 segment is defined by the angle between lines C and D. The C5-thoracic segment is defined by the angle between line D and the global reference.

in the fluoroscopic video, with a precision of 0.1°. The absolute rotation of each component in global coordinates was not the focus, but rather the motion of each component relative to adjacent components (Trendelenburg rotation of the OR table would result in global “extension” of all components, but no flexion or extension of the vertebrae relative to one another.)

Motion segments were defined by two vertebrae, similar to Sawin and Todd,<sup>9</sup> and denoted M0-1 for occiput-C1, M1-2 for C1-C2, and M2-5 for C2-C5. (Figure 1). Motion segment M5-T comprised C5 through whatever vertebrae remained stationary on the backboard. The relative angle between the two bones of each motion segment at any point in time was denoted  $A0-1_{\text{TIME}}$ ,  $A1-2_{\text{TIME}}$ ,  $A2-5_{\text{TIME}}$ , and  $A5-T_{\text{TIME}}$ .

TABLE Patient characteristics

Characteristic	Group 1 Macintosh and Shikani (n = 12)	Group 2 Shikani and Macintosh (n = 11)
Age (yr)	50 ± 18	52 ± 16
Height (cm)	165 ± 10	170 ± 10
Weight (kg)	78 ± 12	85 ± 18
BMI (kg m <sup>-2</sup> )	29 ± 4	29 ± 5
Gender (male/female)	4 / 8	6 / 5
Mallampati score (1 / 2 / 3 / 4)	3 / 7 / 1 / 0	5 / 4 / 2 / 0
TMD (3 fingers)	12	11
Neck rating	All supple	All supple
ASA rating (1 / 2 / 3)	4 / 3 / 5	1 / 6 / 4

TMD = thyromental distance; BMI = body mass index.

The reference for the occiput was defined by a line between the base of the sella and the opisthion (Figure 1). The C1 reference was a line between the lower cortical margin of the anterior arch of C1 and the lower cortical margin of the C1 spinous process. The C2 reference was a line between the anterior, inferior margin of the C2 body and the lower cortical margin of the C2 spinous process. The C5 reference line was a tangent along the superior end-plate of the C5 vertebral body. The stationary vertebrae of segment M5-T were not visible on the fluoroscopy but were defined by the global reference. When necessary, other anatomic landmarks were used by the radiologist, remaining consistent for a given subject. This was acceptable since the study compared the change in the angle of the motion segments, so any consistent landmarks would suffice.

The first frame of each fluoroscopic sequence provided the baseline angles for the motion segments. Viewing the sequence in real time, at various speeds, and on a frame-by-frame basis, the varying angle of each motion segment was analyzed to determine the maximum change in angle from the baseline values. Extension was arbitrarily defined as positive and flexion as negative.<sup>4,9</sup> The duration and maximum change (mean ± standard deviation) for each SOS laryngoscopy was compared to those with direct Macintosh laryngoscopy at each motion segment, using a Student's *t* test. The fluoroscopic films were analyzed independently by two radiologists. As blinding of the radiologists was not feasible, the fluoroscopic videos were presented to the radiologists in random order, with no two sequences from the same patient

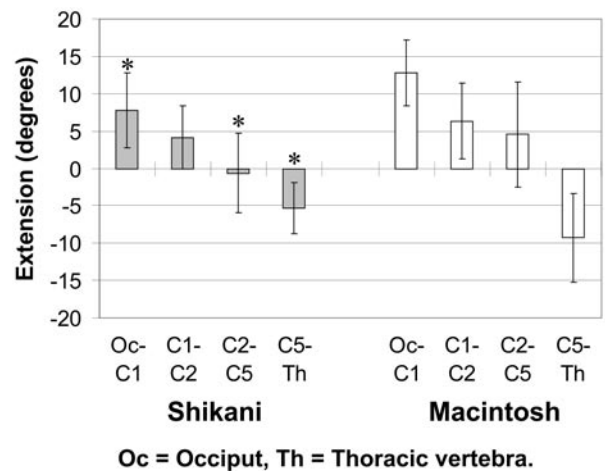


FIGURE 2 Segmental cervical spine movement with the Shikani Optical Stylet *vs* Macintosh use. \**P* = 0.002, 0.001, and 0.02, respectively. Shikani Optical Stylet is different from corresponding C-spine location with Macintosh.

appearing within five video clips. Where differences corresponding to > 1.5° were measured, the films were then reviewed together to obtain consensus.

Using data from the control group of Turkstra *et al.*<sup>4</sup> and a surmised 15% reduction in C-spine movement for clinical significance, the sample size was calculated to be ten patients for each group, for *P* = 0.05 and power = 0.80. Twenty-four patients were recruited to allow for patient dropout and/or potential failure of the fluoroscopic equipment or recording device.

## Results

Recruitment was limited by the availability of the fluoroscopy equipment. Thirty-six patients were invited to participate in the study between March and May of 2006. Five patients declined and seven patients had fluoroscopy or surgery cancelled prior to randomization; 24 patients were enrolled and gave written consent. One patient was excluded from the study after induction when active reflux disease (exclusion criteria) was observed after induction, despite a negative history. No patients were lost to follow-up. The patient characteristics are summarized in the Table.

Patients underwent SOS use and direct Macintosh laryngoscopy in random order; C-spine motion was compared. Figure 2 shows the distribution of C-spine movement during laryngoscopy with the two techniques. Cervical spine motion was 31% (*P* = 0.002), 95% (*P* = 0.001), and 39% less (*P* = 0.02) during

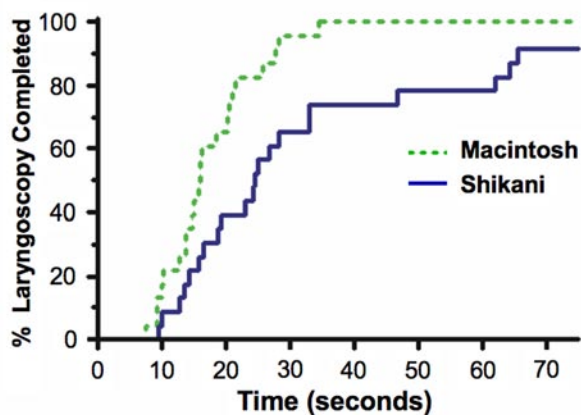


FIGURE 3 Percentage of laryngoscopy completed *vs* time with the Shikani Optical Stylet *vs* Macintosh use. Solid = Shikani Optical Stylet; Dashed = Macintosh;  $P < 0.01$ .

laryngoscopy with SOS compared to the Macintosh blade, at the occiput-C1, C2-C5, and C5-thoracic motion segments, respectively. There was no significant difference in C-spine movement at the C1-C2 segment.

The time required for Macintosh laryngoscopy was  $17 \pm 7$  sec compared to  $28 \pm 17$  sec for the SOS,  $P < 0.01$ . Figure 3 shows a Kaplan-Meier plot illustrating the percentage of laryngoscopy completed *vs* time. There were two failures out of 23 attempts at visualization using the SOS (one in each group) when no view of the glottic structures was obtained with the SOS within the predefined time limit. In both cases, the patient was found to have a Cormack and Lehane<sup>14</sup> grade 1 view during direct laryngoscopy with a Macintosh 3 blade. There were no laryngoscopy failures using the Macintosh blade.

### Discussion

The major finding of this study is that, in healthy individuals with in-line stabilization, there is less C-spine motion with the SOS in comparison to the Macintosh laryngoscope, at the occiput-C1, C2-C5, and C5-thoracic motion segments. On average, C-spine movement was reduced 55% at these segments using the SOS *vs* direct Macintosh laryngoscopy. There was no significant difference at the C1-C2 motion segment. Thus, the SOS may be a useful tool for experienced users in the setting of “uncleared” C-spine patients, particularly if a C-spine injury is suspected in the occiput-C1, C2-C5, or C5-thoracic areas of the C-spine.

Although cadaveric studies found significant C-spine movement with airway maneuvers such as chin lift and jaw thrust,<sup>3,7</sup> an *in vivo* study using manual in-line stabilization has demonstrated that the maximal C-spine movement takes place during the intubation as opposed to during ventilation with bag and mask, making the choice of intubating technique germane.<sup>4</sup>

The anticipated speed benefit of the added fiberoptic view did not materialize in the study. Laryngoscopy with SOS averaged  $28 \pm 17$  sec, 65% longer than observed with a Macintosh blade ( $17 \pm 7$  sec). The clinical relevance of an additional 11 sec for intubation will depend on the specific patient scenario. As shown in Figure 3, the greatest difference was at 40–60 sec interval, where only 70% of patients would have laryngoscopy completed *vs* 100% with a Macintosh blade. This duration data includes only equipment use, and not equipment set-up time, which might also favour Macintosh laryngoscopy in time-critical situations, depending on location logistical considerations.

In addition, there were two of 23 patients (8.7%) whose glottic opening could not be visualized using the SOS within the allotted time, making intubation improbable. Jaw thrust and elevation of the tongue did not result in visualization. This failure rate must bear patient specific consideration when choosing an intubation technique. The duration and failure data is similar to that found by Young *et al.*<sup>15</sup> but more successful than found by Agro *et al.*<sup>16</sup> This suggests that, in the setting of in-line stabilization, there is a time and success cost associated with the reduced C-spine movement the SOS affords. There was no indication in preoperative assessment to suggest difficult laryngoscopy and we found Cormack<sup>14</sup> grade 1 view in both cases using the Macintosh blade. This suggests that some routine patients may have pharyngeal geometry which does not lend itself to straightforward glottic view with the SOS.

During direct Macintosh laryngoscopy, the ETT was positioned at the glottic opening while attempting to minimize C-spine movement, which usually resulted in Cormack and Lehane<sup>14</sup> grade 2 view. During SOS use, the fiberoptic view universally resulted in a “Cormack grade 1” view for the 21 successful laryngoscopy attempts, and this improved view may be valuable in situations of suspected trauma to the larynx or vocal cords.

The reduction in C-spine movement with the SOS is similar to that observed in our previous study of the Trachlight<sup>4</sup> at segments occiput-C1, C2-C5, and C5-thoracic. The SOS did not reduce C-spine movement at segment C1-C2, unlike the Trachlight, which reduced C-spine movement at segment C1-C2. This

might have been due to the fact that the Trachlight allowed a tighter radius of stylet curvature or that the Trachlight's lower mass allowed for easier maneuverability.

Cervical spine motion during Macintosh laryngoscopy was similar in this study to that observed in a previous control (Macintosh) group of Turkstra *et al.*<sup>4</sup> This suggests that manual in-line stabilization by the assistant in this study was similarly effective to the technique in the previous study where the patient's head was immobilized to a Mayfield horseshoe with tape.

To facilitate laryngoscopy, the ideal initial position for the patient's head and neck has not been standardized.<sup>2,3,17</sup> As a result, patients in different studies will begin with different initial extension and/or flexion positions of the C-spine. Accordingly, the amount of extension or flexion observed during laryngoscopy will likely be different. For this reason, patients in this study were randomized after positioning, to prevent a potential "initial position" bias from influencing the results.

Each patient underwent laryngoscopy twice, but intubation once. With the first laryngoscopy, the ETT was not inserted into the trachea to avoid the potential trauma of multiple intubations. Criteria were established, however, to verify that ETT placement could have proceeded with the first laryngoscopy. With SOS use, positioning the SOS tip between the vocal cords was accepted as successful placement. With Macintosh use, the position of the ETT tip visualized at the glottis defined successful placement. Identical criteria were used for the second laryngoscopy. In addition, when the fluoroscopic videos were reviewed with "soft tissue windows", (contrast and brightness settings) the position of the ETT tip at the glottis was confirmed for each laryngoscopy.

Cricoid pressure<sup>18</sup> was not used during this study. There is still some controversy in regards to actual benefit in patients with C-spine injury.<sup>3,18</sup> The application of cricoid pressure was avoided because it would have involved additional hand *x-ray* exposure and could potentially obscure areas of interest on fluoroscopy.

A limitation of this study is that we examined healthy patients as a model for C-spine injured patients. It is likely, however, that an intubating technique that reduces C-spine motion in healthy patients may also result in reduced vertebral movement in the setting of an unstable C-spine, since the technique may involve less force being applied to the cervical structures.

In conclusion, we have shown that C-spine motion was reduced 55% using the SOS as compared to the Macintosh blade in the setting of in-line stabilization,

but only at the occiput-C1, C2-C5, and C5-thoracic segments. On average, the SOS required 11 sec longer than the Macintosh blade, and was unsuccessful in two of 23 patients. In experienced hands, the SOS may be beneficial to reduce C-spine movement during tracheal intubation, while modestly increasing the time required to establish the patient's airway.

### Acknowledgements

This study was funded from Departmental sources. The authors have no conflicts of interest with the manufacturers of any of the medical devices used in this study. The Shikani Optical Stylet for this trial was provided on loan from Clarus Medical Inc. for the duration of the trial. Clarus Medical Inc. had no input with respect to study design or data analysis, and provided no financial support. Trial Registration: ClinicalTrials.gov (NCT00310999).

### References

- 1 American College of Surgeons Committee on Trauma. Advanced Trauma Life Support for Doctors. Student Course Manual, 7<sup>th</sup> ed. 2004; 1: 2, 7.
- 2 Crosby E. Airway management after upper cervical spine injury: what have we learned? *Can J Anesth* 2002; 49: 733-44.
- 3 Crosby ET. Airway management in adults after cervical spine trauma. *Anesthesiology* 2006; 104: 1293-318.
- 4 Turkstra TP, Craen RA, Pelz DM, Gelb AW. Cervical spine motion: a fluoroscopic comparison during intubation with lighted stylet, GlideScope and Macintosh laryngoscope. *Anesth Analg* 2005; 101: 910-5.
- 5 Brimacombe J, Keller C, Kunzel KH, Gaber O, Boehler M, Pubringer F. Cervical spine motion during airway management: a cinefluoroscopic study of posteriorly destabilized third cervical vertebrae in human cadavers. *Anesth Analg* 2000; 91: 1274-8.
- 6 Waltl B, Melischek M, Schuschmig C, et al. Tracheal intubation and cervical spine excursion: direct laryngoscopy vs. intubating laryngeal mask. *Anaesthesia* 2001; 56: 221-6.
- 7 Hauswald M, Sklar DP, Tandberg D, Garcia JF. Cervical spine movement during airway management: cinefluoroscopic appraisal in human cadavers. *Am J Emerg Med* 1991; 9: 535-8.
- 8 Lennarson PJ, Smith DW, Sawin PD, Todd MM, Sato Y, Traynelis VC. Cervical spinal motion during intubation: efficacy of stabilization maneuvers in the setting of complete segmental instability. *J Neurosurg* 2001; 94(2 Suppl): 265-70.
- 9 Sawin PD, Todd MM, Traynelis VC, et al. Cervical spine motion with direct laryngoscopy and orotracheal intubation. An in vivo cinefluoroscopic study of

- subjects without cervical abnormality. *Anesthesiology* 1996; 85: 26–36.
- 10 *Watts AD, Gelb AW, Bach DB, Pelz DM.* Comparison of the Bullard and Macintosh laryngoscopes for endotracheal intubation of patients with a potential cervical spine injury. *Anesthesiology* 1997; 87: 1335–42.
  - 11 *Hastings RH, Vigil AC, Hanna R, Yang BY, Sartoris DJ.* Cervical spine movement during laryngoscopy with the Bullard, Macintosh, and Miller laryngoscopes. *Anesthesiology* 1995; 82: 859–69.
  - 12 *Gerling MC, Davis DP, Hamilton RS, et al.* Effect of surgical cricothyrotomy on the unstable cervical spine in a cadaver model of intubation. *J Emerg Med* 2001; 20: 1–5.
  - 13 *Rudolph C, Schneider JP, Wallenborn J, Schaffranietz L.* Movement of the upper cervical spine during laryngoscopy: a comparison of the Bonfils intubation fibroscope and the Macintosh laryngoscope. *Anaesthesia* 2005; 60: 668–72.
  - 14 *Cormack RS, Lehane J.* Difficult tracheal intubation in obstetrics, *Anaesthesia* 1984; 39: 1105–11.
  - 15 *Young CF, Rosenblatt WH.* A better mousetrap? Evaluation of the user interface, complications, and efficacy of the Shikani Optical Stylet™ for orotracheal intubation. Available from URL; <http://www.clarus-medical.com/airway-management/Documents/ChrisYoung.doc> (accessed October 29, 2006).
  - 16 *Agro F, Cataldo R, Carassiti M, Costa F.* The seeing stylet: a new device for tracheal intubation. *Resuscitation* 2000; 44: 177–80.
  - 17 *Lennarson PJ, Smith DW, Todd MM, et al.* Segmental cervical spinal motion during orotracheal intubation of the intact and injured spine with and without external stabilization. *J Neurosurg* 2000; 92(2 Suppl): 201–6.
  - 18 *Brimacombe JR, Berry AM.* Cricoid pressure. *Can J Anaesth* 1997; 44: 414–25.



Maligne Lake in Jasper National Park – Alberta